



# American Society for Gastrointestinal Endoscopy guideline on the role of endoscopy in the management of acute colonic pseudo-obstruction and colonic volvulus

**Mariam Naveed, MD,<sup>1,\*</sup> Laith H. Jamil, MD, FASGE,<sup>2,\*</sup> Larissa L. Fujii-Lau, MD,<sup>3</sup> Mohammad Al-Haddad, MD,<sup>4</sup> James L. Buxbaum, MD, FASGE,<sup>5</sup> Douglas S. Fishman, MD, FASGE,<sup>6</sup> Terry L. Jue, MD, FASGE,<sup>7</sup> Joanna K. Law, MD,<sup>8</sup> Jeffrey K. Lee, MD,<sup>9</sup> Bashar J. Qumseya, MD, MPH,<sup>10</sup> Mandeep S. Sawhney, MD, FASGE,<sup>11</sup> Nirav Thosani, MD,<sup>12</sup> Andrew C. Storm, MD,<sup>13</sup> Audrey H. Calderwood, MD, FASGE,<sup>14</sup> Mouen A. Khashab, MD,<sup>15</sup> Sachin B. Wani, MD, FASGE,<sup>16</sup> ASGE Standards of Practice Committee Chair**

This document was reviewed and approved by the Governing Board of the American Society for Gastrointestinal Endoscopy.

Colonic volvulus and acute colonic pseudo-obstruction (ACPO) are 2 causes of benign large-bowel obstruction. Colonic volvulus occurs most commonly in the sigmoid colon as a result of bowel twisting along its mesenteric axis. In contrast, the exact pathophysiology of ACPO is poorly understood, with the prevailing hypothesis being altered regulation of colonic function by the autonomic nervous system resulting in colonic distention in the absence of mechanical blockage. Prompt diagnosis and intervention leads to improved outcomes for both diagnoses. Endoscopy may play a role in the evaluation and management of both entities. The purpose of this document from the American Society for Gastrointestinal Endoscopy's Standards of Practice Committee is to provide an update on the evaluation and endoscopic management of sigmoid volvulus and ACPO. (Gastrointest Endosc 2020;91:228-35.)

This document is a focused update on the role of endoscopy in the management of colonic volvulus and acute colonic pseudo-obstruction (ACPO) prepared by the Standards of Practice Committee of the American Society for Gastrointestinal Endoscopy. For guidelines on the role of endoscopy in the management of malignant colon obstruction and benign colonic strictures, please refer to the 2010 guideline, "The role of endoscopy in the management of patients with known and suspected colonic obstruction and pseudo-obstruction."<sup>1</sup> In preparing this document, a comprehensive search of the medical literature was performed by using EMBASE, PubMed, and Web of Science from 2009 through March 2019 that related to the topic of "endoscopic management of colon volvulus and acute colonic pseudo-obstruction" by using the keyword(s) *endoscopy*, *colon volvulus*, *gastrointestinal endoscopy*, *acute colonic pseudo-obstruction*, *sigmoid volvulus*, *endoscopic procedures*, and *procedures*. The search was supplemented by accessing the "related articles" feature of PubMed, with articles identified on PubMed as the

references. Pertinent studies published in English were reviewed. Additional references were obtained from the bibliographies of the identified articles and from recommendations of expert consultants. When little or no data existed from well-designed prospective trials, emphasis was given to results from large series and recommendations from recognized experts. Guidelines for appropriate use of endoscopy are based on a critical review of the available data and expert consensus at the time the guidelines were drafted. Further controlled clinical studies may be needed to clarify aspects of this guideline. This guideline may be revised as necessary to account for changes in technology, new data, or other aspects of clinical practice.

## INTRODUCTION

Large-bowel obstruction accounts for approximately 25% of all intestinal obstructions.<sup>2</sup> Obstruction can be either functional or mechanical in origin. Colonic volvulus is the most common cause of benign mechanical obstruction and accounts for approximately 3.5% of all cases of large-bowel obstruction in the United States and up to 50% in areas such as Africa and the Middle East.<sup>3</sup> Functional bowel obstruction, an example of which

is ACPO, occurs as a result of alterations in GI motility and can be characterized by a clinical picture suggestive of mechanical obstruction with no demonstrable cause of obstruction noted on imaging.<sup>4</sup>

Given that patients with both colon volvulus and ACPO may present with abdominal pain and distention, demographic factors and abdominal cross-sectional imaging with CT are used to differentiate between the 2 etiologies and mechanical obstruction other than volvulus. Typically, patients at risk for either colon volvulus or ACPO are elderly, debilitated, and hospitalized, with multiple medical comorbidities. Abdominal CT findings of ACPO include colonic dilatation with possible transition zone and no obvious mechanical cause of obstruction, whereas patients with volvulus may present with dilated colon and mesenteric whirl sign. Early recognition and management are essential in both clinical entities because a delay in diagnosis is associated with substantial morbidity and mortality.<sup>5</sup> For this focused update, a literature review from the date of the latest reference in the previous guideline was performed specifically on the role of endoscopy in the management of colon volvulus and ACPO.

## COLON VOLVULUS

### Etiology and clinical presentation

Acute colonic volvulus, resulting from torsion of a redundant segment of colon along its mesenteric axis, most commonly occurs in the sigmoid colon or cecum.<sup>6</sup> Risk factors for colonic volvulus include anatomic factors such as a long redundant colon with a narrow mesenteric attachment, constipation, colonic dysmotility, and prior abdominal surgery.<sup>7</sup> Although sigmoid volvulus is more common in adult men >70 years old, African Americans, and patients with diabetes and neuropsychiatric disorders, cecal volvulus is more prevalent in younger females.<sup>3</sup> Common presenting symptoms include nausea, vomiting, abdominal pain, distention, and obstipation.

Contrast-enhanced CT has replaced abdominal radiographs and water-soluble contrast enemas as the preferred diagnostic study for both cecal and sigmoid volvulus.<sup>8</sup> Abdominal radiographs are diagnostic in 60% of patients with sigmoid volvulus, whereas CT has been shown to confirm diagnosis of sigmoid volvulus with near 100% sensitivity and >90% specificity.<sup>9-11</sup>

### Endoscopic treatment

Patients with signs of peritonitis, perforation, or with recurrent or unsuccessful nonoperative decompression should be referred immediately for surgical management.<sup>12</sup> In the absence of these aforementioned adverse events, nonoperative detorsion with flexible sigmoidoscopy with or without placement of a decompression tube is considered first-line therapy in the management of sigmoid volvulus.<sup>13</sup> In contrast, surgical management is preferred

over colonoscopy in patients with cecal volvulus because endoscopic reduction is rarely effective and is associated with a higher risk of perforation.<sup>13,14</sup>

The endoscopic appearance of sigmoid volvulus is characterized by 2 points of abruptly twisted or converging colon mucosa. Between the distal and proximal points of torsion, the colon is dilated as a result of closed-loop obstruction. Endoscopic treatment involves inserting the endoscope to the point of obstruction and gently attempting to pass the endoscope through the twisted segment. If this is successful, aggressive decompression of the dilated colon segment should be performed and will often result in spontaneous detorsion. In addition to being a therapeutic modality, endoscopy allows for assessment of colon viability.<sup>15</sup> The success rate of endoscopic detorsion of sigmoid volvulus ranges from 55% to 94%.<sup>9,16-18</sup> In a single-center retrospective study of 21 patients with sigmoid volvulus, the success rate of endoscopic detorsion was 61.9%, whereas the rest required emergency surgical treatment. Absence of abdominal tenderness, use of laxatives, and history of open abdominal surgery were identified as factors predictive of successful endoscopic detorsion.<sup>19</sup> Although randomized controlled data are lacking, placement of a decompression tube proximal to the point of torsion after successful detorsion is advocated in efforts to maintain the reduction and allow for continued colonic decompression.<sup>6,9,11,13,20,21</sup>

In pediatric patients, endoscopic detorsion is also the preferred method for sigmoid volvulus reduction.<sup>22</sup> One of the initial series in children demonstrated efficacy of only 47%.<sup>23</sup> However, a more recent series of 13 cases demonstrated that decompression was effective in all cases.<sup>22</sup> It is also common practice to place a rectal tube while awaiting surgery. Recurrence of volvulus is reported in up to 100% of pediatric cases.<sup>22-24</sup>

### Recurrence

Recurrence rates of up to 86% have been reported after successful endoscopic decompression.<sup>6,25</sup> In a recent single-center cohort study of 168 patients with sigmoid volvulus, recurrence was observed in 84% of successful nonoperative decompression cases within a median of 58 days, with a median of 2 recurrences.<sup>26</sup> In a retrospective study,<sup>16</sup> a recurrence rate of 46.2% was noted, with 6 of 13 patients experiencing recurrent volvulus. Because the mortality rate of patients presenting with recurrent sigmoid volvulus is high, elective surgical treatment, specifically sigmoid colectomy, is generally recommended in candidate patients during the index admission or shortly thereafter.<sup>13</sup>

### Advanced endoscopic therapy

In patients who are not candidates for surgery, advanced endoscopic techniques such as percutaneous endoscopic colostomy (PEC) and percutaneous endoscopic sigmoidopexy have been suggested as management options. Both techniques aim to fix the involved colon

segment to the anterior abdominal wall, restricting its mobility and thus preventing recurrent volvulus. Although case series exist with patients successfully undergoing these procedures for recurrent sigmoid volvulus, it is important to note that both modalities are associated with a relatively high incidence of immediate and delayed serious adverse events, including infection, tube migration, perforation, obstruction, abdominal wall bleeding, and death.<sup>27-29</sup> Frank et al<sup>30</sup> reported a 21% risk of morbidity and 5% risk of mortality associated with PEC placement in patients with recurrent sigmoid volvulus.

## ACUTE COLONIC PSEUDO-OBSTRUCTION

### Etiology and clinical presentation

ACPO, synonymous with Ogilvie's syndrome, is characterized by an acute presentation of massive dilation of the large intestine in the absence of a mechanical etiology.<sup>4</sup> Most patients are hospitalized at onset. The exact pathogenesis remains to be elucidated, but current evidence suggests an alteration in the autonomic nervous system resulting in colonic atony and pseudo-obstruction.<sup>31,32</sup> Several risk factors have been identified in the development of ACPO, including critical illness, recent surgical procedure, metabolic imbalance, and nonoperative trauma.<sup>33</sup> Although the true incidence remains unknown, in a retrospective cohort study using a national admissions database, the annual incidence of ACPO was approximately 100 cases of 100,000 inpatient admissions per year.<sup>34</sup>

### Adverse events

The most serious adverse events of ACPO are ischemia and perforation, with an increased risk for these adverse events in patients with cecal diameters greater than 10 to 12 cm and in those with duration of distention exceeding 6 days.<sup>33,35</sup> At the time of colonoscopy, approximately 10% of patients have some degree of ischemia in the right-sided colon. Risk of spontaneous perforation is estimated to be between 3% and 25%, with up to 50% risk of mortality in the event of a perforation.<sup>33,36,37</sup>

Imaging is crucial in establishing a diagnosis because mechanical obstruction must be excluded. Plain-film abdominal radiography is usually sufficient in making a diagnosis, although it cannot always reliably distinguish mechanical from functional causes of obstruction.<sup>38</sup> Water-soluble contrast enema of the rectum and distal colon is another diagnostic option, although CT has largely replaced contrast enema studies. It is worth noting that mechanical obstruction rarely occurs in a patient admitted for unrelated illnesses (eg, pneumonia, elective non-GI surgery).

### Conservative therapy

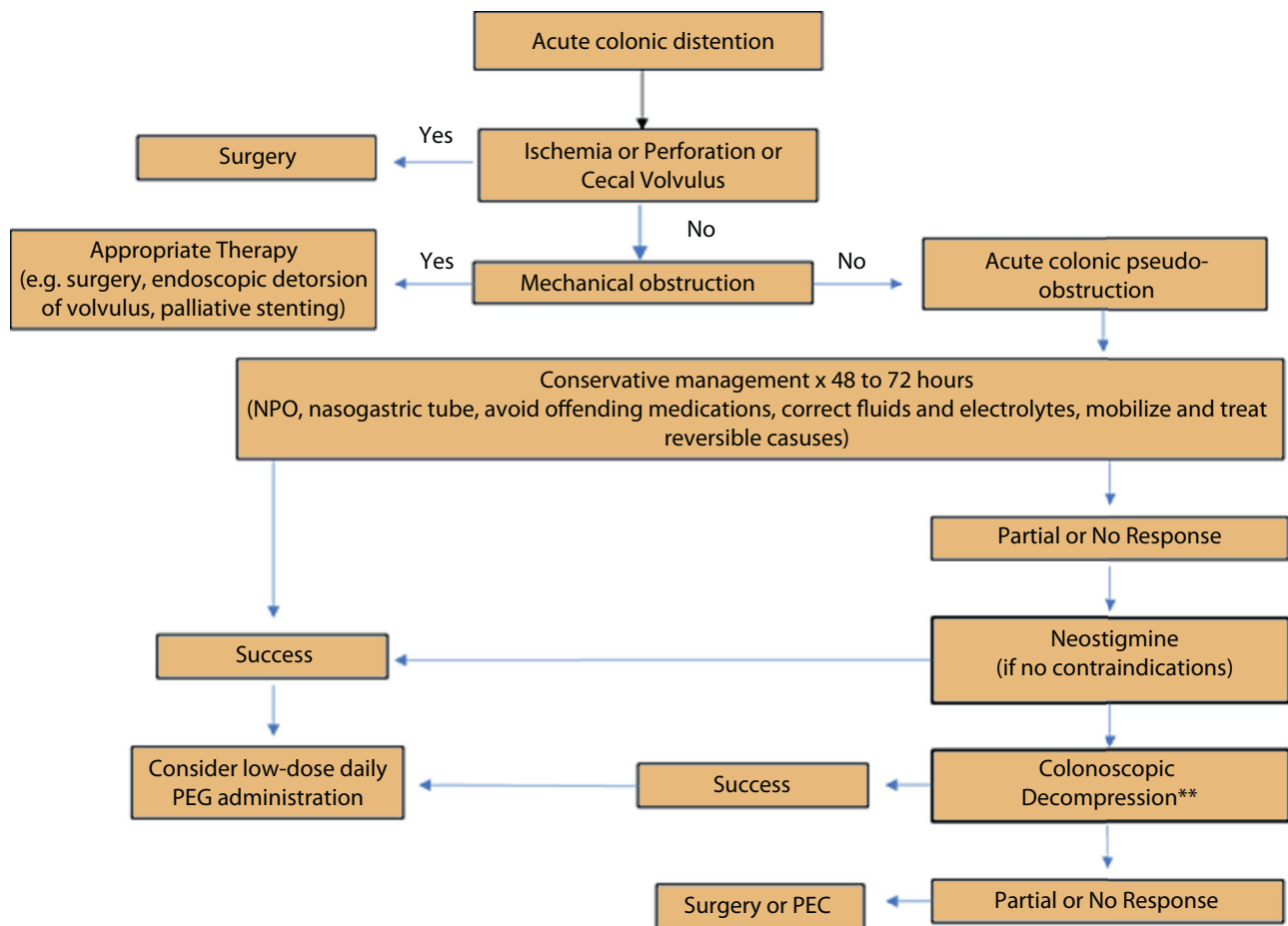
In patients with uncomplicated ACPO (absence of ischemia, peritonitis, cecal diameter >12 cm, and/or significant abdominal pain), conservative management remains

first-line therapy. This includes identification and discontinuation of predisposing factors (eg, narcotic use), correction of fluid and electrolyte disorders, maintaining patient with nothing by mouth, ambulation, treatment of infections, and decompression of the proximal gut with a nasogastric tube. Overall success rate of this approach is variable, with rates ranging from 77% to 96%.<sup>39,40</sup> Serial assessment of the cecal diameter is prudent given the risk of perforation with cecal diameters greater than 12 cm.<sup>33</sup> For patients who are not candidates for conservative management or in whom symptoms persist beyond 48 to 72 hours, either pharmacologic therapy or endoscopic decompression should be considered as the next step in the treatment algorithm (Fig. 1). One retrospective study found colonic decompression performed by experienced endoscopists to be a more effective initial therapy compared with neostigmine. However, there was no decrease in length of hospital stay, intensive care unit stay, or need for colostomy.<sup>41</sup>

### Pharmacologic therapy

Neostigmine, a short-acting anticholinesterase parasympathomimetic agent, remains the pharmacologic agent of choice in the management of ACPO. Continuous monitoring of cardiac rhythm and respiratory status and immediate access to atropine in the event of bradycardia are required during drug administration. Coadministration of glycopyrrolate may be useful in preventing side effects of the medication, including hypersalivation and bronchospasm.<sup>42</sup> Other common adverse events include nausea, vomiting, diarrhea, abdominal pain, and sweating. Neostigmine is contraindicated in patients with evidence of intestinal or urinary obstruction and known hypersensitivity reaction. Relative contraindications include bradycardia, asthma, renal insufficiency, peptic ulcer disease, recent myocardial infarction, and acidosis.<sup>43</sup>

Three placebo-controlled, double-blind randomized trials have demonstrated neostigmine to be effective in 85% to 94% of cases.<sup>44-46</sup> In a meta-analysis by Valle and Godoy,<sup>47</sup> resolution of ACPO was significantly higher in patients who received 1 dose of neostigmine (2-5 mg) as compared with placebo (89.2% [range, 84.6%-95.2%] vs 14.8%). A systematic review reported that neostigmine was associated with improvement in clinical symptoms, reduction in time to resolution, and reduction of recurrence in patients who failed conservative management.<sup>48</sup> Reduced duration of ACPO in patients who received neostigmine versus placebo alone has been demonstrated in other studies.<sup>49</sup> In patients who fail an initial dose of neostigmine, are partial responders, or have recurrence, a second dose has been associated with clinical response in 40% to 100%.<sup>40,50,51</sup> Male gender, younger age, postsurgical status, and having electrolyte imbalance are risk factors for nonresponse to neostigmine. Daily administration of polyethylene glycol via nasogastric tube has also been shown to decrease recurrence.<sup>51</sup>



**Figure 1.** Management of acute colonic pseudo-obstruction. \*\*Limited recent data suggest that colonic decompression may be superior to neostigmine as first-line therapy for acute colonic pseudo-obstruction refractory to conservative management; however, these study results need to be supported further before definitive clinical recommendations can be made.

Although neostigmine has traditionally been administered intravenously in bolus dosing for treatment of ACPO, studies have noted success with alternative routes of administration. In a recent, multicenter, retrospective, observational study of 182 patients with ileus, ACPO, or refractory constipation, subcutaneous neostigmine resulted in passage of stool within a median time of 29 hours.<sup>52</sup> Increasing evidence also supports the role for continuous infusion of neostigmine in patients who are refractory to bolus dosing. White and Sandhu<sup>53</sup> described the successful use of continuous infusion of .4 mg/h neostigmine (5 mg neostigmine in 50 mL of .9% normal saline solution) in a patient with ACPO refractory to 3 slow bolus doses of neostigmine. This protocol was first described by van der Spoel et al<sup>45</sup> in patients with critical illness-related colonic ileus. A continuous neostigmine infusion of .4 to .8 mg/h over 24 hours resulted in passage of stool and flatus in 19 of 24 patients in comparison with 0 patients in the placebo arm.<sup>45</sup> A recent retrospective study comparing clinical response of intermittent bolus versus continuous infusion noted that the initial clinical response was similar between both groups (62.2% vs

81.6%,  $P = .6$ ). Continuous-infusion neostigmine, however, was associated with greater bowel diameter reduction at 24 hours.<sup>54</sup> Ilban et al<sup>55</sup> noted no significant difference between patients who received bolus dosing (2 mg in 15 minutes) versus those who received continuous intravenous infusion (.4 mg neostigmine/h); however, the mean time to treatment response was shorter in the bolus dosing group compared with the infusion group (165 minutes vs 510 minutes,  $P = .001$ ). Continuous intravenous infusion may be associated with decreased side effects compared with bolus dosing.<sup>48,54</sup>

Several additional pharmacologic agents have been used for patients who have not responded to treatment with neostigmine, including oral pyridostigmine, a long-acting acetylcholinesterase inhibitor; peripherally acting  $\mu$ -opioid receptor antagonists such as methylnaltrexone; and traditional prokinetics such as metoclopramide and erythromycin. Pyridostigmine, used routinely in the management of myasthenia gravis, has been shown to successfully treat ACPO refractory to neostigmine and endoscopic decompression.<sup>56</sup> Weinstock and Chang<sup>57</sup> noted resolution of opioid-induced ACPO using



methylnaltrexone in 1 patient who failed treatment with neostigmine. Prucalopride, a second generation 5-HT<sub>4</sub> receptor partial agonist, has been shown to successfully treat a patient with acute refractory pseudo-obstruction.<sup>58</sup> Further research into the safety and efficacy of these agents is warranted before their routine use can be recommended in the management of ACPO.

### Endoscopic decompression

Colonoscopic decompression is an important method for managing patients with ACPO. Traditionally, colonic decompression has been reserved for patients with persistent and marked colonic dilatation who have failed to respond to conservative measures, those refractory to medical management, or in whom neostigmine is contraindicated.<sup>34</sup> Younger age at the time of diagnosis, abdominal distention as a chief complaint, and greater cecal diameter have been identified as independently associated with poor response to medical treatment.<sup>59</sup>

The efficacy of colonoscopic decompression has not been established in randomized trials. However, based on available data, initial and sustained colonic decompression from colonoscopy has been noted in up to 95% of patients.<sup>36,37</sup> The procedure should be performed by an experienced endoscopist using water infusion and minimal to no insufflation of carbon dioxide rather than air. Sedation with benzodiazepines or other non-narcotic medication is preferred, because narcotics potentiate colonic atony. The colon should also be unprepped, and an attempt should be made to reach at least the distal transverse colon, after which extensive suctioning of air is recommended.<sup>60</sup> There is an approximately 2% risk of perforation with endoscopic decompression and 1% risk of mortality.<sup>5,61</sup> Repeat colonoscopy is fairly commonplace given 40% risk of recurrence, especially in patients in whom a decompression tube is not placed.<sup>62</sup> Randomized controlled trial data are lacking in support of decompression tubes. Cohort studies provide contradictory data on whether decompression tubes provide additional benefit.<sup>37,61,63-65</sup> Evidence supports that polyethylene glycol solution after endoscopy can lower recurrence rate.<sup>51</sup> As previously noted, benefits of endoscopic decompression extend beyond treatment because it also allows for simultaneous evaluation of the colonic mucosa. It is important to exclude perforation before performing endoscopic decompression with a plain abdominal x-ray performed within several hours before the procedure, especially in those patients with fever, leukocytosis, or worsening abdominal pain.

### Comparison of medical and endoscopic therapy

Although no prospective randomized studies compare endoscopic decompression and pharmacologic treatment, 2 retrospective studies independently found colonoscopic

decompression to be superior to neostigmine. In a retrospective 10-year review of 100 patients with ACPO, Tsirlin et al<sup>63</sup> found colonoscopic decompression to be superior to neostigmine both after 1 (75% vs 35.5%,  $P = .0002$ ) and 2 interventions (84.6 vs 55.6%,  $P = .0031$ ). The risk of perforation was equivalent in both groups.<sup>63</sup> In a retrospective, nonrandomized, clinical study of sequential patients with ACPO, Peker et al<sup>41</sup> demonstrated colonic decompression was more effective than neostigmine as an initial therapy and was more effective at avoiding a second treatment modality. Further, no significant difference in outcome was noted in either group of patients who eventually required surgery. Other reviews have found the 2 treatment modalities to be equivalent.<sup>66</sup> The evidence supporting first-line colonoscopic therapy in managing ACPO is limited, and these study results need to be further supported before definitive clinical recommendations can be made.

### Endoscopic and percutaneous colostomy of the cecum

An alternate method of decompression includes percutaneous endoscopic colostomy of the cecum (PEC-cecum), which can be used in the treatment of cecal volvulus and ACPO. PEC-cecum tubes, placed radiographically or via endoscopy, have reported success rates of up to 100%.<sup>67,68</sup> Nevertheless, this procedure is invasive, and serious adverse events have been noted including wound infection, bleeding or hematoma formation, perforation, granuloma, and buried bumper.<sup>69</sup> PEC-cecum tubes can be placed through a combined endoscopic and radiologic approach in a manner analogous to percutaneous endoscopic gastrostomy tube placement or via the "introducer" method, which uses T-fasteners to secure the colon to the abdominal wall.<sup>70</sup> Studies comparing efficacy of PEC tubes with other methods of decompression are lacking.

### Surgical therapy

For patients in whom conservative, pharmacologic, and endoscopic treatment options fail, surgical intervention is the next appropriate step in management. Patients presenting with peritonitis, ischemia, perforation, clinical deterioration, or cecal diameter greater than 12 cm should also be referred for surgery. Because mortality rates are substantial in patients with ACPO who require surgical intervention, all efforts should be made to manage these patients nonoperatively. In patients with ischemic or perforated bowel, surgical mortality as high as 44% has been reported.<sup>33</sup> Surgical treatment options include surgically placed cecostomy tube, percutaneous cecostomy, or subtotal colectomy. Surgically placed cecostomy tubes, however, are associated with substantial morbidity and mortality.<sup>67</sup> Female gender, emergent admission, and increased comorbidities (specifically chronic obstructive pulmonary disease and metastatic cancer) have been identified as independent risk factors of colonoscopy failure.

## RECOMMENDATIONS

1. For patients with uncomplicated sigmoid volvulus, we suggest endoscopy as the initial treatment modality. After successful detorsion, placement of decompression tube should be considered to maintain reduction and decrease risk of recurrence. (++)
2. For patients with sigmoid volvulus, we suggest surgical consultation during index admission given the high risk of recurrent volvulus and high morbidity and mortality associated with each episode. (+++)
3. For patients with cecal volvulus, we recommend pursuit of surgical management as initial treatment modality and avoidance of endoscopic intervention given the high risk of perforation. (+++)
4. For patients with colon volvulus with overt perforation or signs of peritonitis, we recommend surgical management. (+++)
5. For patients with uncomplicated ACPO (absence of ischemia, peritonitis, cecal diameter <12 cm, and/or significant abdominal pain), we recommend conservative therapy as the preferred initial management including identifying and correcting potentially contributing metabolic, infectious, and pharmacologic factors. (+++)
6. For patients with ACPO who are not candidates for conservative therapy, have failed conservative therapy (up to 72 hours), or are at risk for perforation and have no contraindication to its use, we recommend pharmacologic therapy with neostigmine (2 mg over 3-5 minutes) with appropriate cardiovascular monitoring. (+++)
7. For patients with ACPO who do not respond to a first dose of neostigmine, we suggest the administration of a second dose of neostigmine. (+)
8. For patients with ACPO refractory to bolus dosing of neostigmine, we suggest alternative routes of neostigmine administration including subcutaneous or continuous intravenous infusion. (+)
9. For patients with ACPO who are not candidates for conservative therapy or have failed conservative therapy (up to 72 hours) and have no contraindication to endoscopy, we suggest colonic decompression with decompression tube placement as an alternative. (++)
10. For patients with ACPO with overt perforation or signs of peritonitis, we recommend surgical management. (+++)

## REFERENCES

1. ASGE Standards of Practice Committee; Harrison ME, Anderson MA, Appalaneni V, et al. The role of endoscopy in the management of patients with known and suspected colonic obstruction and pseudo-obstruction. *Gastrointest Endosc* 2010;71:669-79.
2. Markogiannakis H, Messaris E, Dardamanis D, et al. Acute mechanical bowel obstruction: clinical presentation, etiology, management and outcome. *World J Gastroenterol* 2007;13:432-7.
3. Halabi WJ, Jafari MD, Kang CY, et al. Colonic volvulus in the United States: trends, outcomes, and predictors of mortality. *Ann Surg* 2014;259:293-301.
4. Coulie B, Camilleri M. Intestinal pseudo-obstruction. *Annu Rev Med* 1999;50:37-55.
5. Kahi CJ, Rex DK. Bowel obstruction and pseudo-obstruction. *Gastroenterol Clin North Am* 2003;32:1229-47.
6. Ballantyne GH, Brandner MD, Beart RW Jr, et al. Volvulus of the colon. Incidence and mortality. *Ann Surg* 1985;202:83-92.
7. Mulas C, Bruna M, Garcia-Armengol J, et al. Management of colonic volvulus. Experience in 75 patients. *Rev Esp Enferm Dig* 2010;102:239-48.
8. Perrot L, Fohlen A, Alves A, et al. Management of the colonic volvulus in 2016. *J Visc Surg* 2016;153:183-92.
9. Atamanalp SS. Treatment of sigmoid volvulus: a single-center experience of 952 patients over 46.5 years. *Tech Coloproctol* 2013;17:561-9.
10. Atamanalp SS, Ozturk G. Sigmoid volvulus in the elderly: outcomes of a 43-year, 453-patient experience. *Surg Today* 2011;41:514-9.
11. Oren D, Atamanalp SS, Aydinli B, et al. An algorithm for the management of sigmoid colon volvulus and the safety of primary resection: experience with 827 cases. *Dis Colon Rectum* 2007;50:489-97.
12. Bruzzi M, Lefevre JH, Desaint B, et al. Management of acute sigmoid volvulus: short- and long-term results. *Colorectal Dis* 2015;17:922-8.
13. Vogel JD, Feingold DL, Stewart DB, et al. Clinical practice guidelines for colon volvulus and acute colonic pseudo-obstruction. *Dis Colon Rectum* 2016;59:589-600.
14. Consorti ET, Liu TH. Diagnosis and treatment of caecal volvulus. *Postgrad Med J* 2005;81:772-6.
15. Turan M, Sen M, Karadayi K, et al. Our sigmoid colon volvulus experience and benefits of colonoscope in detortion process. *Rev Esp Enferm Dig* 2004;96:32-5.
16. Mangiante EC, Croce MA, Fabian TC, et al. Sigmoid volvulus. A four-decade experience. *Am Surg* 1989;55:41-4.
17. Lou Z, Yu ED, Zhang W, et al. Appropriate treatment of acute sigmoid volvulus in the emergency setting. *World J Gastroenterol* 2013;19:4979-83.
18. Queneherve L, Dagouat C, Le Rhun M, et al. Outcomes of first-line endoscopic management for patients with sigmoid volvulus. *Dig Liver Dis* 2019;51:386-90.
19. Iida T, Nakagaki S, Satoh S, et al. Clinical outcomes of sigmoid colon volvulus: identification of the factors associated with successful endoscopic detorsion. *Intest Res* 2017;15:215-20.
20. Kapadia MR. Volvulus of the small bowel and colon. *Clin Colon Rectal Surg* 2017;30:40-5.
21. Tan KK, Chong CS, Sim R. Management of acute sigmoid volvulus: an institution's experience over 9 years. *World J Surg* 2010;34:1943-8.
22. Colinet S, Rebeuh J, Gottrand F, et al. Presentation and endoscopic management of sigmoid volvulus in children. *Eur J Pediatr* 2015;174:965-9.
23. Salas S, Angel CA, Salas N, et al. Sigmoid volvulus in children and adolescents. *J Am Coll Surg* 2000;190:717-23.
24. Parolini F, Orizio P, Bulotta AL, et al. Endoscopic management of sigmoid volvulus in children. *World J Gastrointest Endosc* 2016;8:439-43.
25. Chung YF, Eu KW, Nyam DC, et al. Minimizing recurrence after sigmoid volvulus. *Br J Surg* 1999;86:231-3.
26. Johansson N, Rosemar A, Angenete E. Risk of recurrence of sigmoid volvulus: a single-centre cohort study. *Colorectal Dis* 2018;20:529-35.
27. Baraza W, Brown S, McAlindon M, et al. Percutaneous endoscopic sigmoidopexy: a cost-effective means of treating sigmoid volvulus in Sub-Saharan Africa? *East Afr Med J* 2007;84:1-2.
28. Cowlam S, Watson C, Elltringham M, et al. Percutaneous endoscopic colostomy of the left side of the colon. *Gastrointest Endosc* 2007;65:1007-14.
29. Tin K, Sobani ZA, Anyadike N, et al. Percutaneous endoscopic sigmoidopexy using T-fasteners for management of sigmoid volvulus. *Int J Colorectal Dis* 2017;32:1073-6.

30. Frank L, Moran A, Beaton C. Use of percutaneous endoscopic colostomy (PEC) to treat sigmoid volvulus: a systematic review. *Endosc Int Open* 2016;4:E737-41.
31. Stephenson BM, Morgan AR, Drake N, et al. Parasympathomimetic decompression of acute colonic pseudo-obstruction. *Lancet* 1993;342:1181-2.
32. Durai R. Colonic pseudo-obstruction. *Singapore Med J* 2009;50:237-44.
33. Vanek VW, Al-Salti M. Acute pseudo-obstruction of the colon (Ogilvie's syndrome). *An analysis of 400 cases. Dis Colon Rectum* 1986;29:203-10.
34. Ross SW, Oommen B, Wormer BA, et al. Acute colonic pseudo-obstruction: defining the epidemiology, treatment, and adverse outcomes of Ogilvie's syndrome. *Am Surg* 2016;82:102-11.
35. Johnson CD, Rice RP, Kelvin FM, et al. The radiologic evaluation of gross cecal distension: emphasis on cecal ileus. *AJR Am J Roentgenol* 1985;145:1211-7.
36. Saunders MD. Acute colonic pseudo-obstruction. *Best Pract Res Clin Gastroenterol* 2007;21:671-87.
37. Saunders MD, Kimmey MB. Systematic review: acute colonic pseudo-obstruction. *Aliment Pharmacol Ther* 2005;22:917-25.
38. Stewart J, Finan PJ, Courtney DF, et al. Does a water soluble contrast enema assist in the management of acute large bowel obstruction: a prospective study of 117 cases. *Br J Surg* 1984;71:799-801.
39. Sloyer AF, Panella VS, Demas BE, et al. Ogilvie's syndrome. Successful management without colonoscopy. *Dig Dis Sci* 1988;33:1391-6.
40. Loftus CG, Harewood GC, Baron TH. Assessment of predictors of response to neostigmine for acute colonic pseudo-obstruction. *Am J Gastroenterol* 2002;97:3118-22.
41. Peker KD, Cikot M, Bozkurt MA, et al. Colonoscopic decompression should be used before neostigmine in the treatment of Ogilvie's syndrome. *Eur J Trauma Emerg Surg* 2017;43:557-66.
42. Howard J, Wigley J, Rosen G, et al. Glycopyrrolate: It's time to review. *J Clin Anesth* 2017;36:51-3.
43. De Giorgio R, Knowles CH. Acute colonic pseudo-obstruction. *Br J Surg* 2009;96:229-39.
44. Ponc R, Saunders MD, Kimmey MB. Neostigmine for the treatment of acute colonic pseudo-obstruction. *N Engl J Med* 1999;341:137-41.
45. van der Spoel JI, Oudemans-van Straaten HM, Stoutenbeek CP, et al. Neostigmine resolves critical illness-related colonic ileus in intensive care patients with multiple organ failure - a prospective, double-blind, placebo-controlled trial. *Intensive Care Med* 2001;27:822-7.
46. Amaro R, Rogers AI. Neostigmine infusion: new standard of care for acute colonic pseudo-obstruction? *Am J Gastroenterol* 2000;95:304-5.
47. Valle RG, Godoy FL. Neostigmine for acute colonic pseudo-obstruction: a meta-analysis. *Ann Med Surg* 2014;3:60-4.
48. Elsner JL, Smith JM, Ensor CR. Intravenous neostigmine for postoperative acute colonic pseudo-obstruction. *Ann Pharmacother* 2012;46:430-5.
49. Kayani B, Spalding DR, Jiao LR, et al. Does neostigmine improve time to resolution of symptoms in acute colonic pseudo-obstruction? *Int J Surg* 2012;10:453-7.
50. Mehta R, John A, Nair P, et al. Factors predicting successful outcome following neostigmine therapy in acute colonic pseudo-obstruction: a prospective study. *J Gastroenterol Hepatol* 2006;21:459-61.
51. Sgouros SN, Vlachogiannakos J, Vassiliadis K, et al. Effect of polyethylene glycol electrolyte balanced solution on patients with acute colonic pseudo obstruction after resolution of colonic dilation: a prospective, randomised, placebo controlled trial. *Gut* 2006;55:638-42.
52. Kram B, Greenland M, Grant M, et al. Efficacy and safety of subcutaneous neostigmine for ileus, acute colonic pseudo-obstruction, or refractory constipation. *Ann Pharmacother* 2018;52:505-12.
53. White L, Sandhu G. Continuous neostigmine infusion versus bolus neostigmine in refractory Ogilvie syndrome. *Am J Emerg Med* 2011;29:576.
54. Smedley LW, Foster DB, Barthol CA, et al. Safety and Efficacy of Intermittent Bolus and Continuous Infusion Neostigmine for Acute Colonic Pseudo-Obstruction. *J Intensive Care Med* 2018;885066618809010.
55. Ilban O, Cicekci F, Celik JB, et al. Neostigmine treatment protocols applied in acute colonic pseudo-obstruction disease: A retrospective comparative study. *Turk J Gastroenterol* 2019;30:228-33.
56. O'Dea CJ, Brookes JH, Wattoo DA. The efficacy of treatment of patients with severe constipation or recurrent pseudo-obstruction with pyridostigmine. *Colorectal Dis* 2010;12:540-8.
57. Weinstock LB, Chang AC. Methylalntrexone for treatment of acute colonic pseudo-obstruction. *J Clin Gastroenterol* 2011;45:883-4.
58. Smart CJ, Ramesh AN. The successful treatment of acute refractory pseudo-obstruction with prucalopride. *Colorectal Dis* 2012;14:e508.
59. Lee KJ, Jung KW, Myung SJ, et al. The clinical characteristics of colonic pseudo-obstruction and the factors associated with medical treatment response: a study based on a multicenter database in Korea. *J Korean Med Sci* 2014;29:699-703.
60. Strodel WE, Nostrant TT, Eckhauser FE, et al. Therapeutic and diagnostic colonoscopy in nonobstructive colonic dilatation. *Ann Surg* 1983;197:416-21.
61. Geller A, Petersen BT, Gostout CJ. Endoscopic decompression for acute colonic pseudo-obstruction. *Gastrointest Endosc* 1996;44:144-50.
62. Rex DK. Colonoscopy and acute colonic pseudo-obstruction. *Gastrointest Endosc Clin N Am* 1997;7:499-508.
63. Tsirlina VB, Zemlyak AY, Avery MJ, et al. Colonoscopy is superior to neostigmine in the treatment of Ogilvie's syndrome. *Am J Surg* 2012;204:849-55; discussion 55.
64. Lavignolle A, Jutel P, Bonhomme J, et al. [Ogilvie's syndrome: results of endoscopic exsufflation in a series of 29 cases]. *Gastroenterol Clin Biol* 1986;10:147-51.
65. Harig JM, Fumo DE, Loo FD, et al. Treatment of acute nontoxic megacolon during colonoscopy: tube placement versus simple decompression. *Gastrointest Endosc* 1988;34:23-7.
66. Bernardi MP, Warrier S, Lynch AC, et al. Acute and chronic pseudo-obstruction: a current update. *ANZ J Surg* 2015;85:709-14.
67. Benacci JC, Wolff BG. Cecostomy. Therapeutic indications and results. *Dis Colon Rectum* 1995;38:530-4.
68. Ramage JI Jr, Baron TH. Percutaneous endoscopic cecostomy: a case series. *Gastrointest Endosc* 2003;57:752-5.
69. Bertolini D, De Saussure P, Chilcott M, et al. Severe delayed complication after percutaneous endoscopic colostomy for chronic intestinal pseudo-obstruction: a case report and review of the literature. *World J Gastroenterol* 2007;13:2255-7.
70. Jain A, Vargas HD. Advances and challenges in the management of acute colonic pseudo-obstruction (ogilvie syndrome). *Clin Colon Rectal Surg* 2012;25:37-45.

*Abbreviations:* ACPO, acute colonic pseudo-obstruction; PEC, percutaneous endoscopic colostomy.

**DISCLOSURE:** The following authors disclosed financial relationships relevant to this publication: M. Al-Haddad: Teaching and research support from Boston Scientific. M.A. Khashab: Consultant for BSCI, Olympus, and Medtronic. S. B. Wani: Consultant to Boston Scientific and Medtronic. All other authors disclosed no financial relationships relevant to this publication.

Received September 4, 2019. Accepted September 4, 2019.

\*Drs Naveed and Jamil contributed equally to this article.

Current affiliations: Advent Health Medical Group, Gastroenterology/Hepatology, Advent Health Hospital Altamonte Springs, Altamonte Springs, Florida, USA (1), Division of Gastroenterology and Hepatology, Beaumont, Royal Oak, Royal Oak, Michigan, USA (2), Gastroenterology Service, The Queen's Medical Center, Honolulu, Hawaii, USA (3), Division of Gastroenterology/Hepatology, Indiana University School of Medicine, Indianapolis, Indiana, USA (4), Division of Gastrointestinal and Liver Diseases, Keck School of Medicine, University of Southern California, Los Angeles, California, USA (5), Department of Gastroenterology, Baylor College of Medicine/

Texas Children's Hospital, Houston, Texas, USA (6), The Permanente Medical Group (7), Department of Gastroenterology (9), Kaiser Permanente San Francisco Medical Center, San Francisco, California, USA; Digestive Disease Institute, Virginia Mason Medical Center, Seattle, Washington, USA (8), Department of Gastroenterology, Archbold Medical Group, Thomasville, Georgia, USA (10), Division of Gastroenterology, Beth Israel Deaconess Medical Center/Harvard Medical School, Boston, Massachusetts, USA (11), Division of Gastroenterology, Hepatology and Nutrition, McGovern Medical School, UTHealth, Houston, Texas, USA (12), Department of

Gastroenterology and Hepatology, Mayo Clinic, Rochester, Minnesota, USA (13), Department of Gastroenterology and Hepatology, Dartmouth Hitchcock Medical Center, Geisel School of Medicine, Lebanon, New Hampshire, USA (14), Division of Gastroenterology and Hepatology, Johns Hopkins University, Baltimore, Maryland, USA (15), Division of Gastroenterology and Hepatology, University of Colorado Anschutz Medical Center, Aurora, Colorado, USA (16).

**Read Articles in Press Online Today!  
Scan the QR code or visit [www.giejournal.org](http://www.giejournal.org)**

*Gastrointestinal Endoscopy* now posts in-press articles online in advance of their appearance in the print edition of the Journal. These articles are available at the *Gastrointestinal Endoscopy* website, [www.giejournal.org](http://www.giejournal.org), by clicking on the "Articles in Press" link, as well as at Elsevier's ScienceDirect website, [www.sciencedirect.com](http://www.sciencedirect.com). Articles in Press represent the final edited text of articles that are accepted for publication but not yet scheduled to appear in the print journal. They are considered officially published as of the date of web publication, which means readers can access the information and authors can cite the research months prior to its availability in print. To cite Articles in Press, include the journal title, year, and the article's Digital Object Identifier (DOI), located in the article footnote. Please visit *Gastrointestinal Endoscopy* online today to read Articles in Press and stay current on the latest research in the field of gastrointestinal endoscopy.

